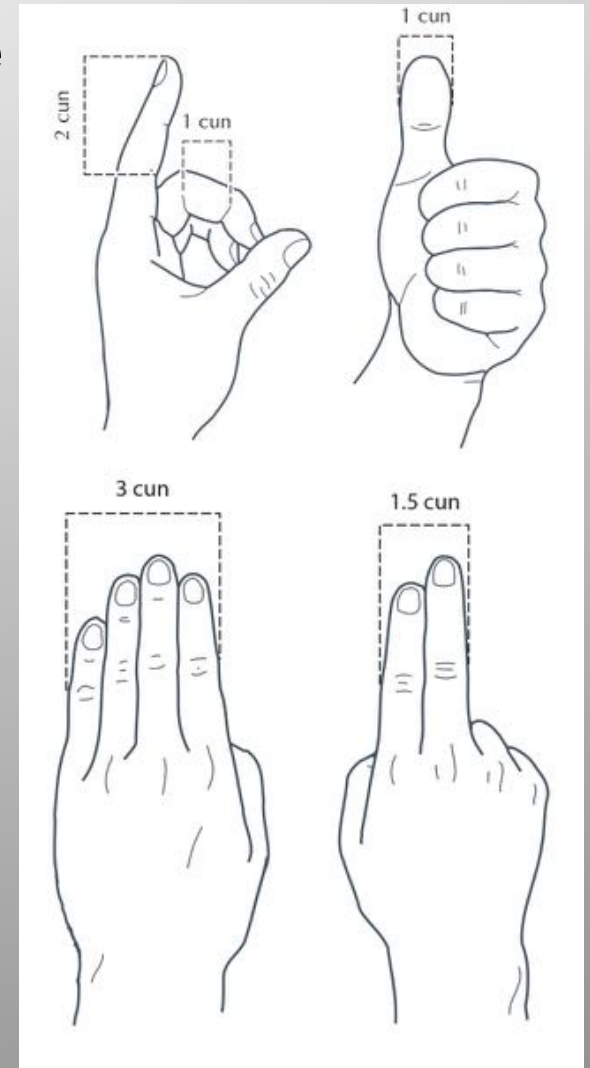
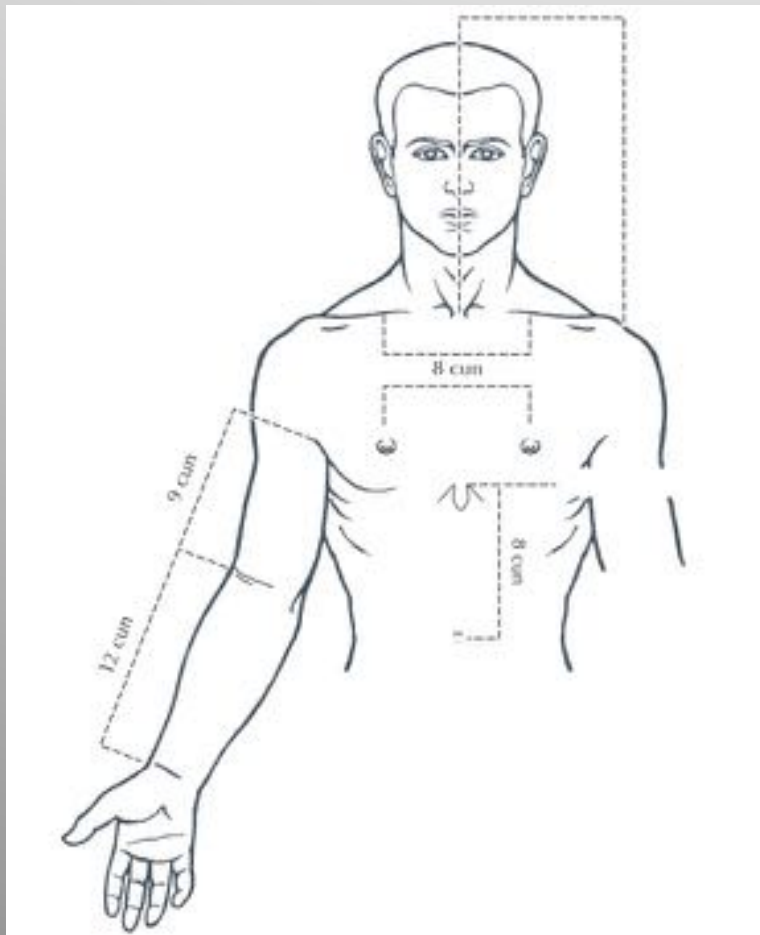


***Point Location:
Large Intestine Meridian***

Hand Yang Ming

Arm Cun Measurements

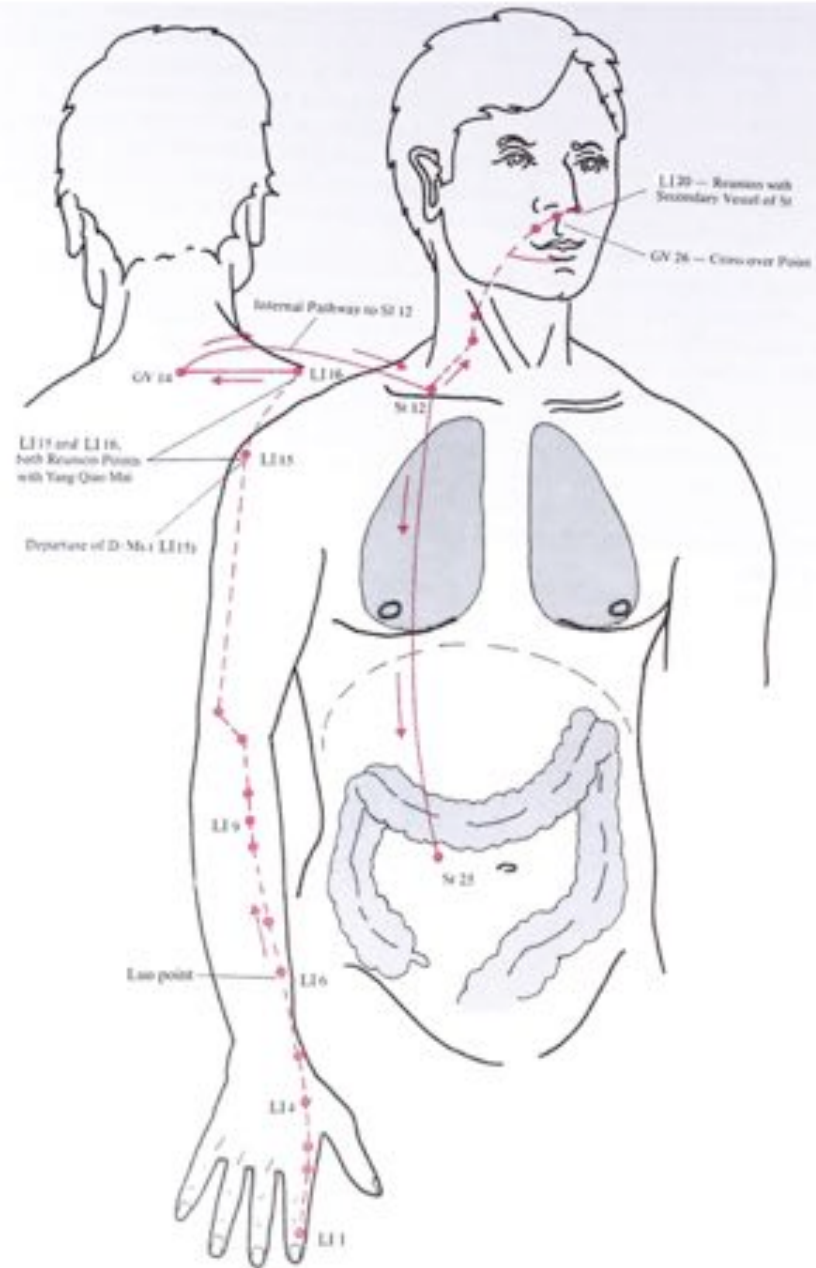
Cun—a proportional unit of measure



LI Meridian

Hand Yang Ming

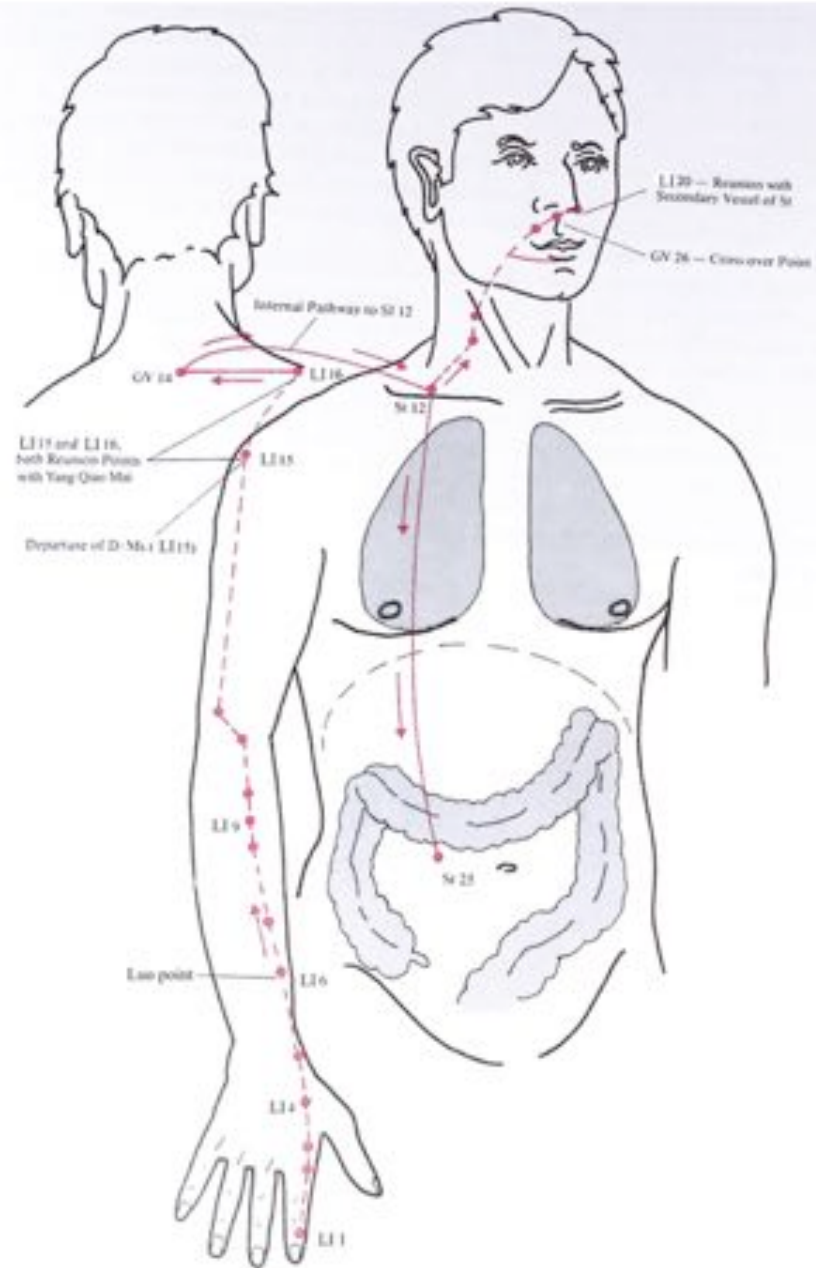
Starts at the radial side of nail at the 2nd digit and goes down the finger to the 2nd metacarpal bone and passes the anatomic snuff box and proceeds up the forearm to the elbow and then up the arm passing over the deltoid insertion to the shoulder joint LI 15, then crosses to the posterior shoulder LI 16 heading to the Yang Meridian meeting point at GV 14 just below the 7th cervical spinous process.



LI Meridian

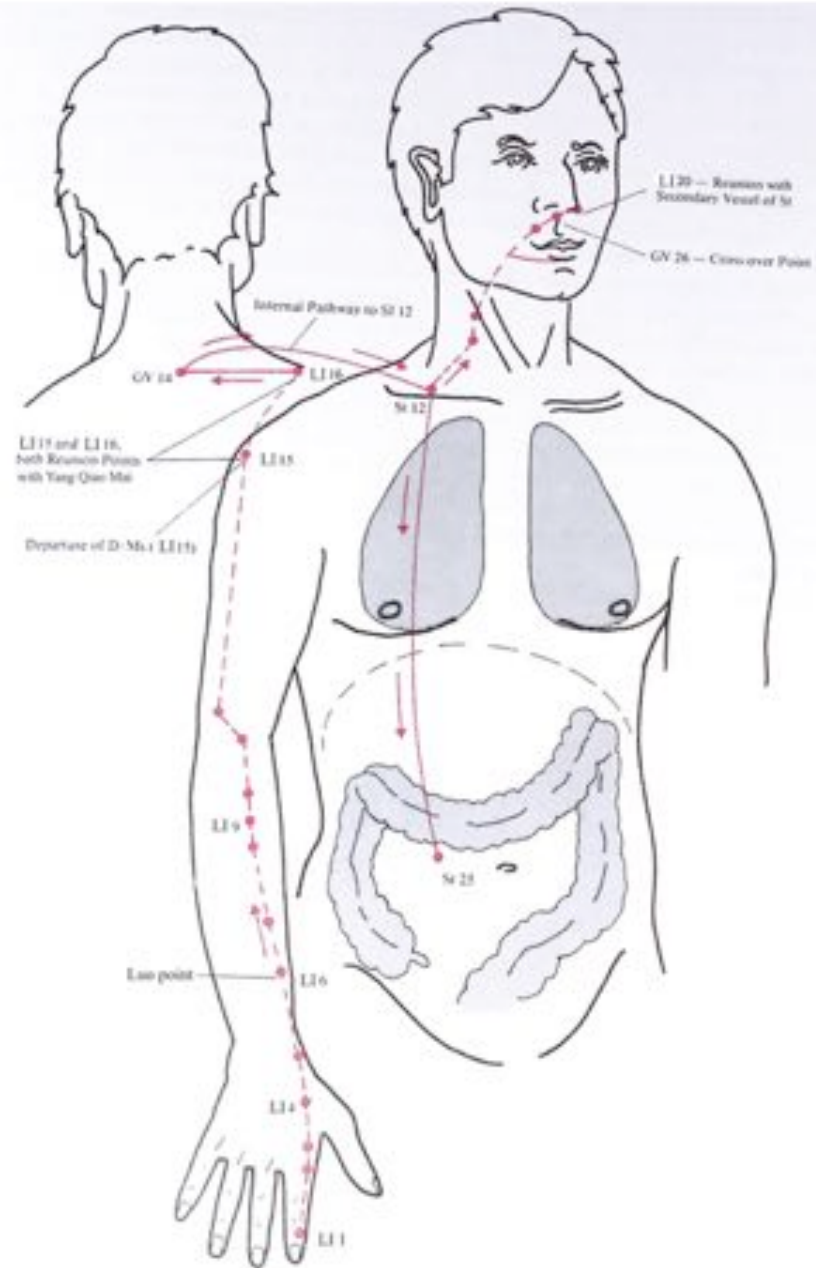
Hand Yang Ming

It then penetrates to the supraclavicular fossa arriving at ST 12 and then heads up the neck, crosses the cheek and enters the lower teeth and gums to CV 24 exiting through then up to the philtrum at GV 26 where it becomes external and then terminates at LI 20 on the opposite side of the nose where it connects with an internal pathway to begin the Stomach Meridian.



LI Meridian Hand Yang Ming

The internal trajectory descends from St 12 in the supraclavicular fossa where it connects to the lung and then down through the diaphragm to enter the large intestine at St 25 (Large Intestine Mu Point).

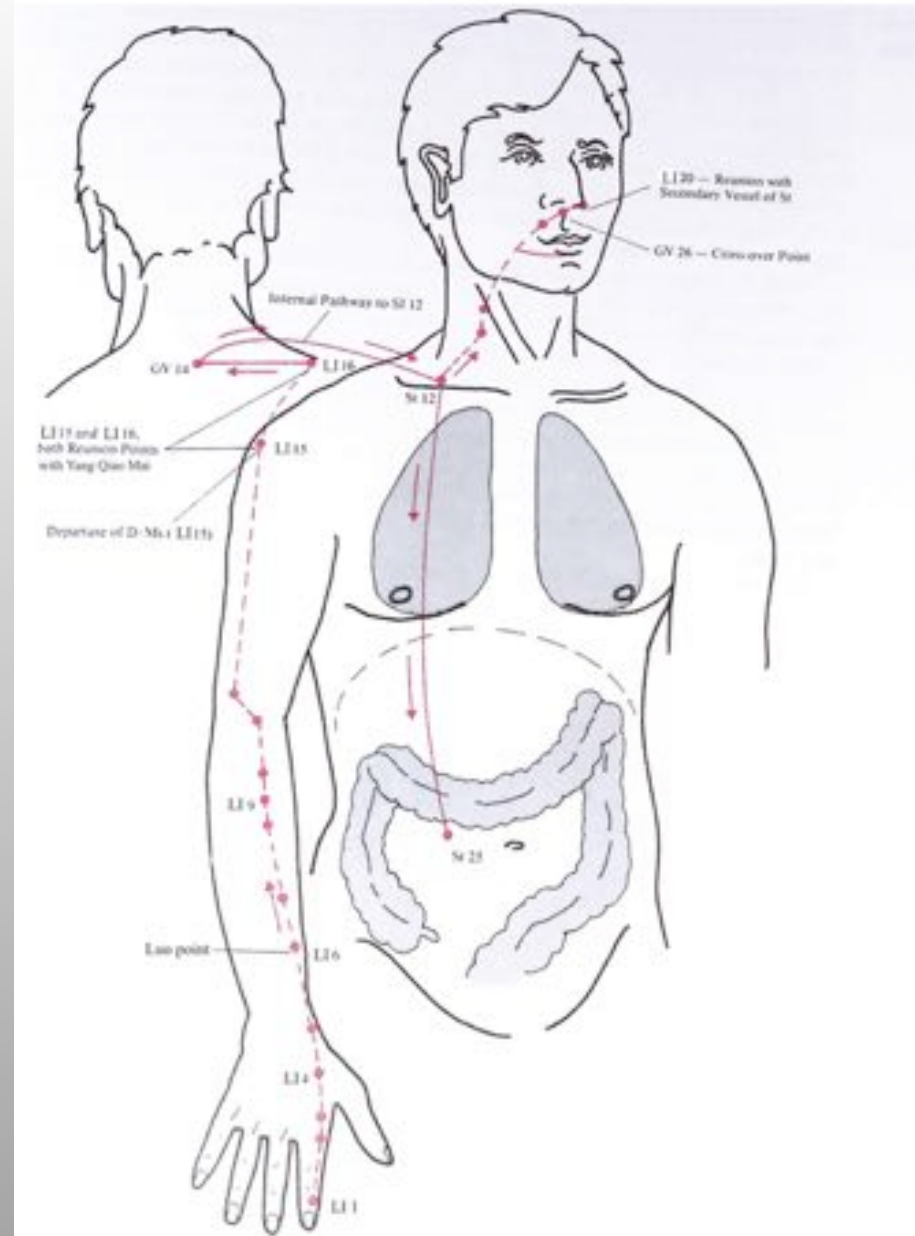


Large Intestine Trajectory



LI Meridian Hand Yang Ming

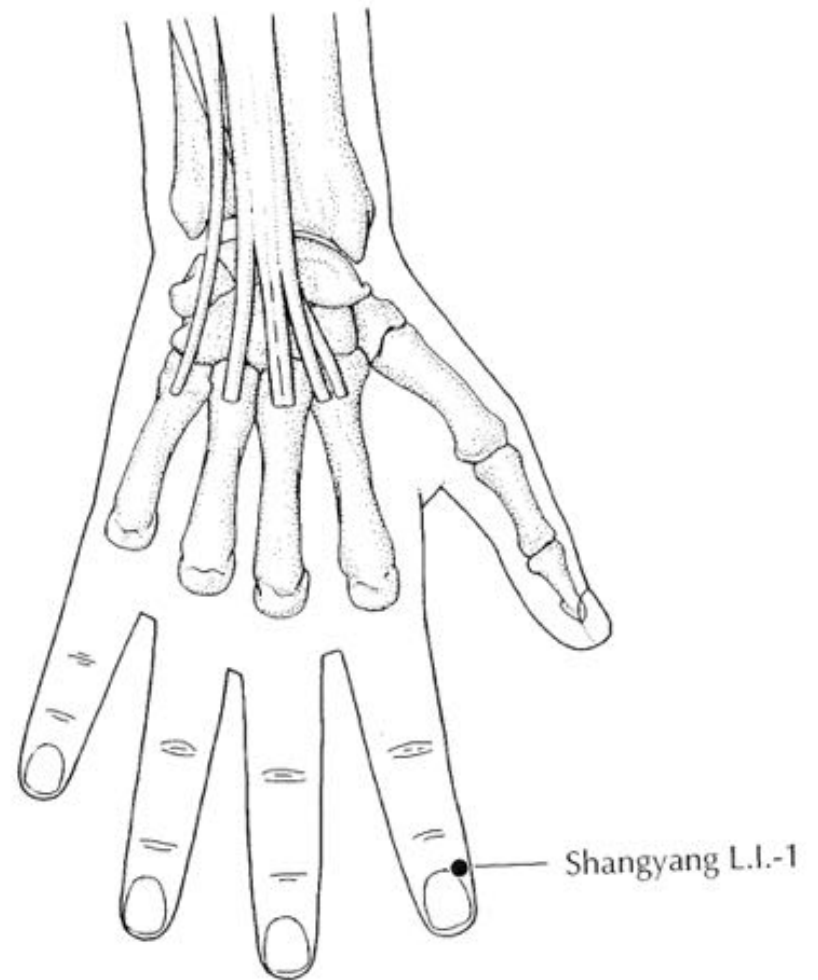
***Points to know: LI 1, 2,
4, 5, 6, 10, 11, 14, 15, 17,
20***



LI Meridian Hand Yang Ming

***LI 1 – (Shangyang –
Metal Yang)***

Located at the
proximal corner on the
lateral aspect of the
second finger's nail.



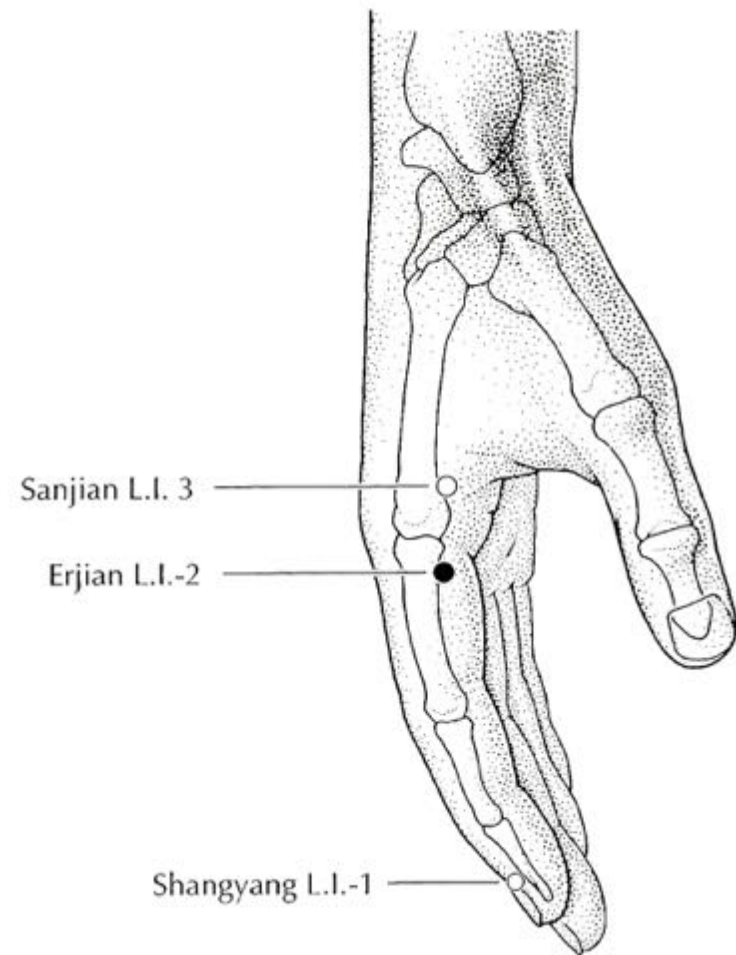
Large Intestine 2 Hand Yang Ming

LI 2 –(*er jian* –Second Space)

On radial border of index 2nd digit, in a depression just distal to the metacarpo-phalangeal (MP) joint.

Japanese LI 2

Master Nagano used point distal to proximal interphalangeal (PIP) joint



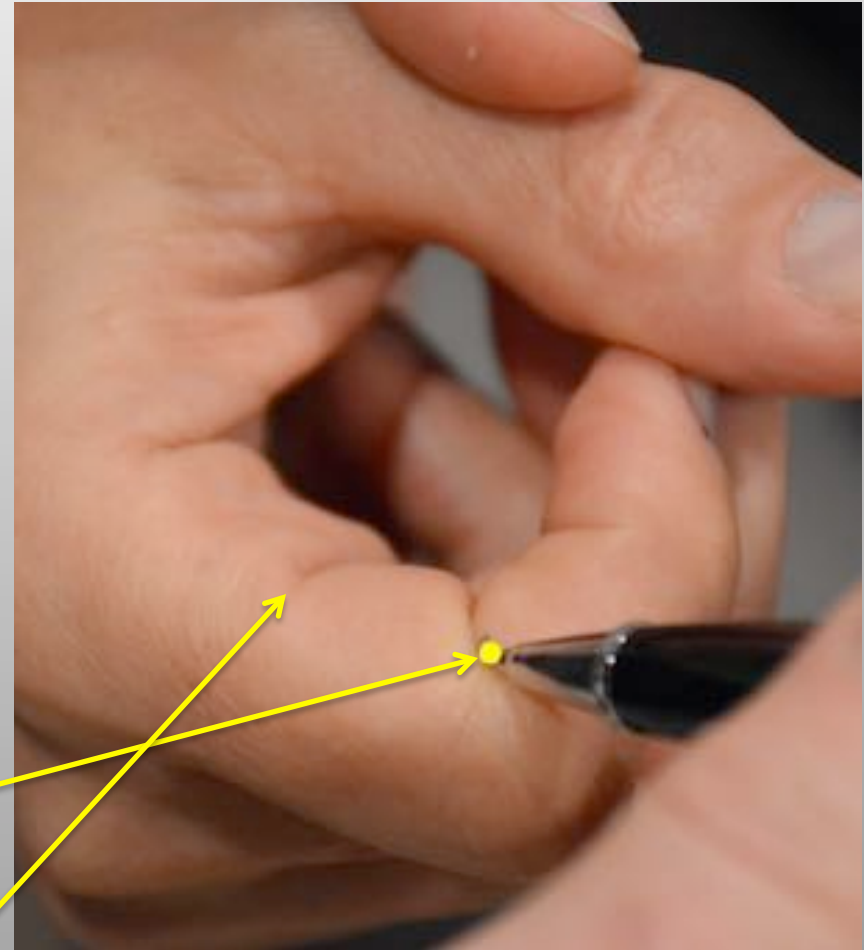
Japanese Large Intestine 2

Japanese LI 2

Master Nagano used point distal to proximal interphalangeal (PIP) joint

Can also be found by curling fingers into loose fist and there will be 3 creases on 2nd finger, the middle crease is the Nagano LI

3rd crease is TCM LI 2

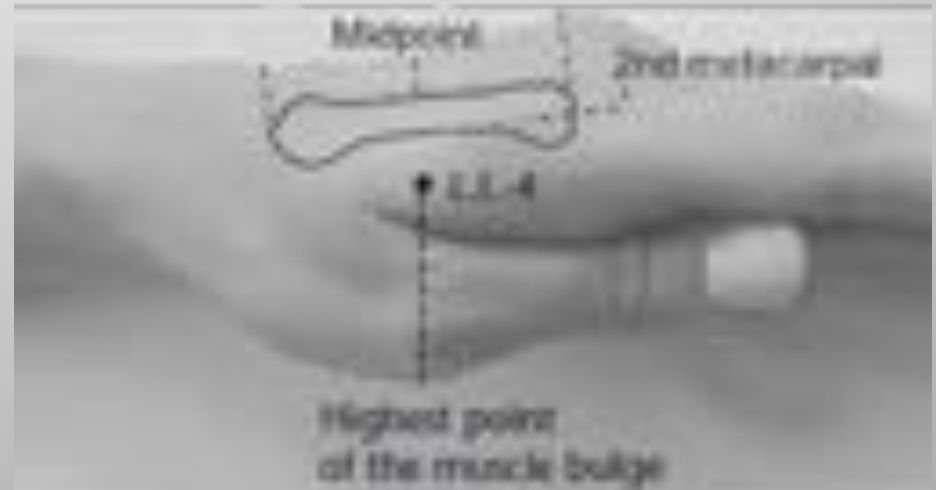

Large Intestine 4

Hand Yang Ming

LI 4 –(*Hegu* -Joining Valley)

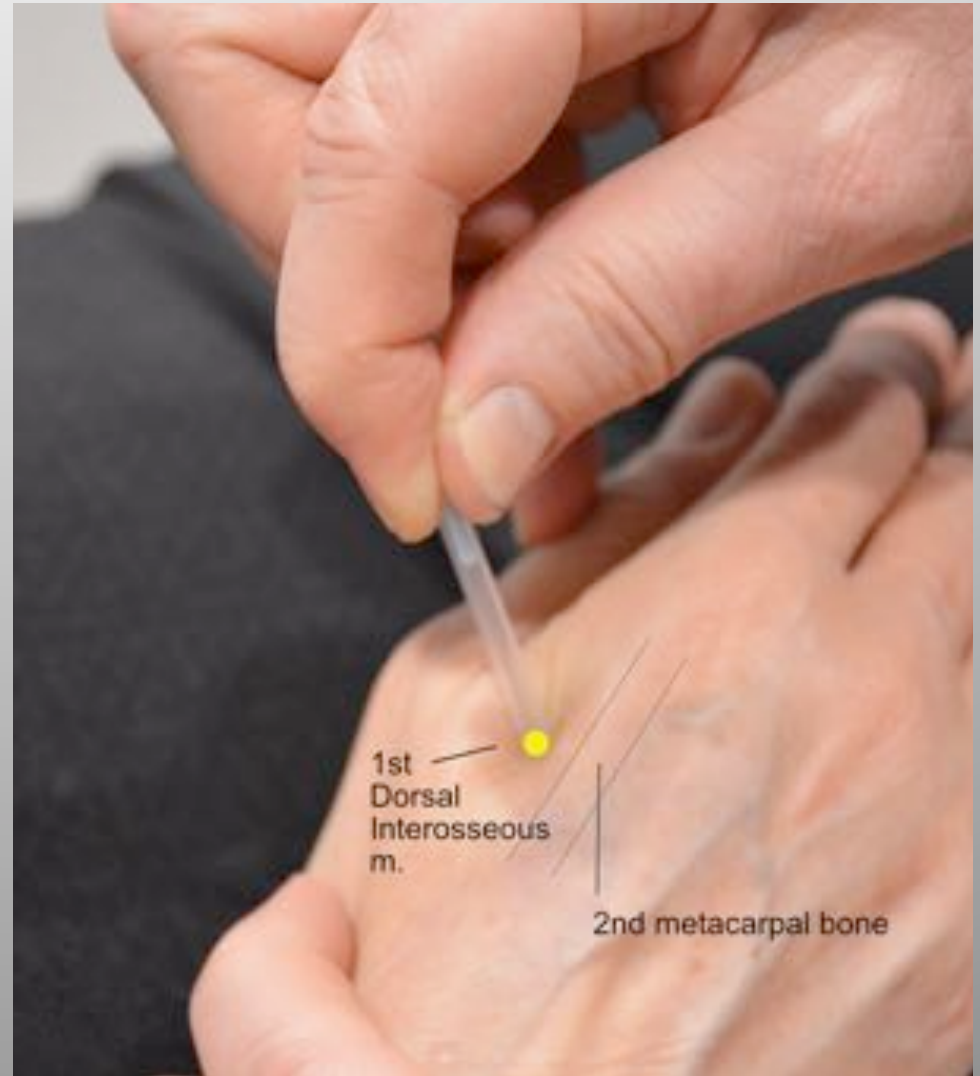
On the dorsum of the hand, between the first and second metacarpal bones at the midpoint of the 2nd metacarpal bone in the mound formed by the muscle belly of the first dorsal interosseous (FDI)



Large Intestine 4 Hand Yang Ming

LI 4 -(Hegu -Joining Valley)

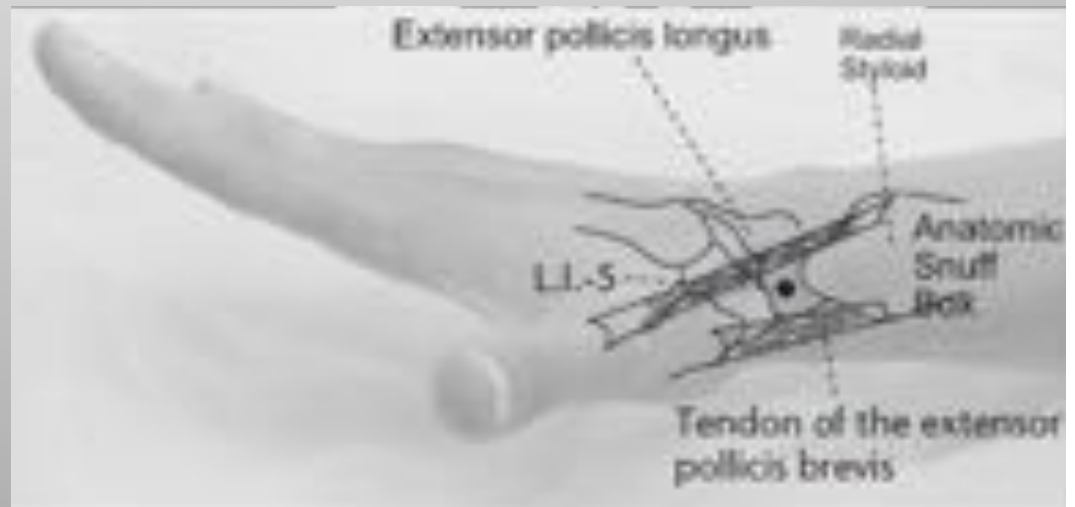
On the dorsum of the hand, between the first and second metacarpal bones at the midpoint of the 2nd metacarpal bone in the mound formed by the muscle belly of the first dorsal interosseous (FDI)



Large Intestine 5 Hand Yang Ming

LI 5 –(*Yangxi* –Yang Stream)

Located on the radial aspect of the wrist, in the center of the anatomical snuffbox, between tendons of the extensor pollicis longus and brevis



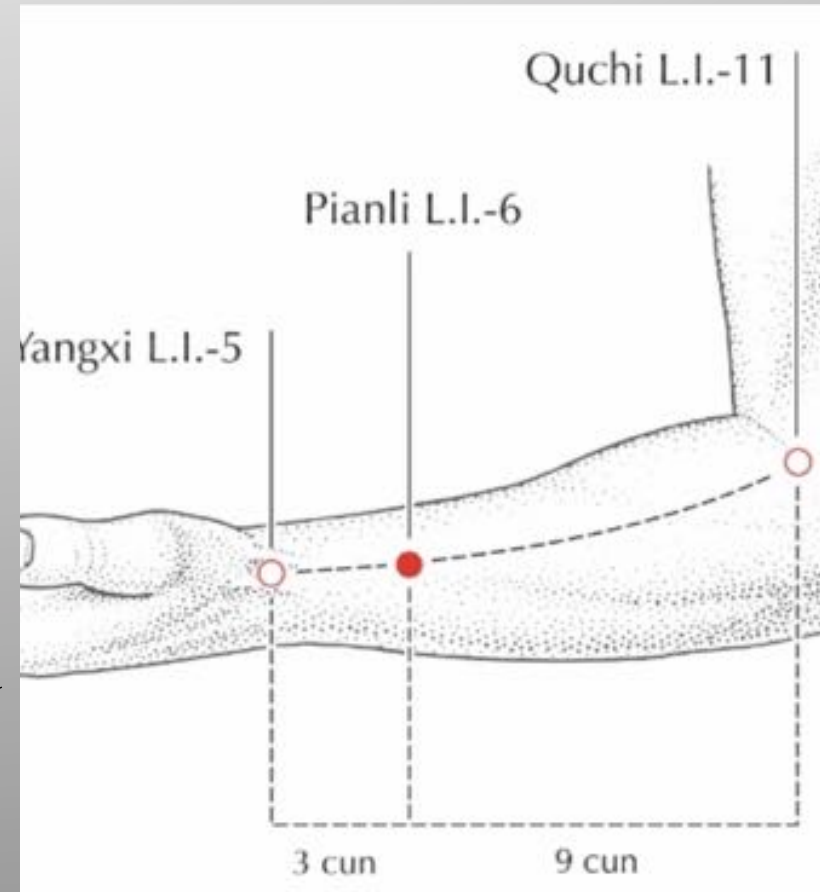
Large Intestine 6 Hand Yang Ming

LI 6 –(*Pianli*–Veering Passage)

Located 3 cun proximal to LI 5
on line formed between LI 11
and LI 5

Japanese LI 6

Master Hukaya states this point is best located when the patient places the second and third finger of one hand over the thumb of the patient hand, found on LI line between two fingers.

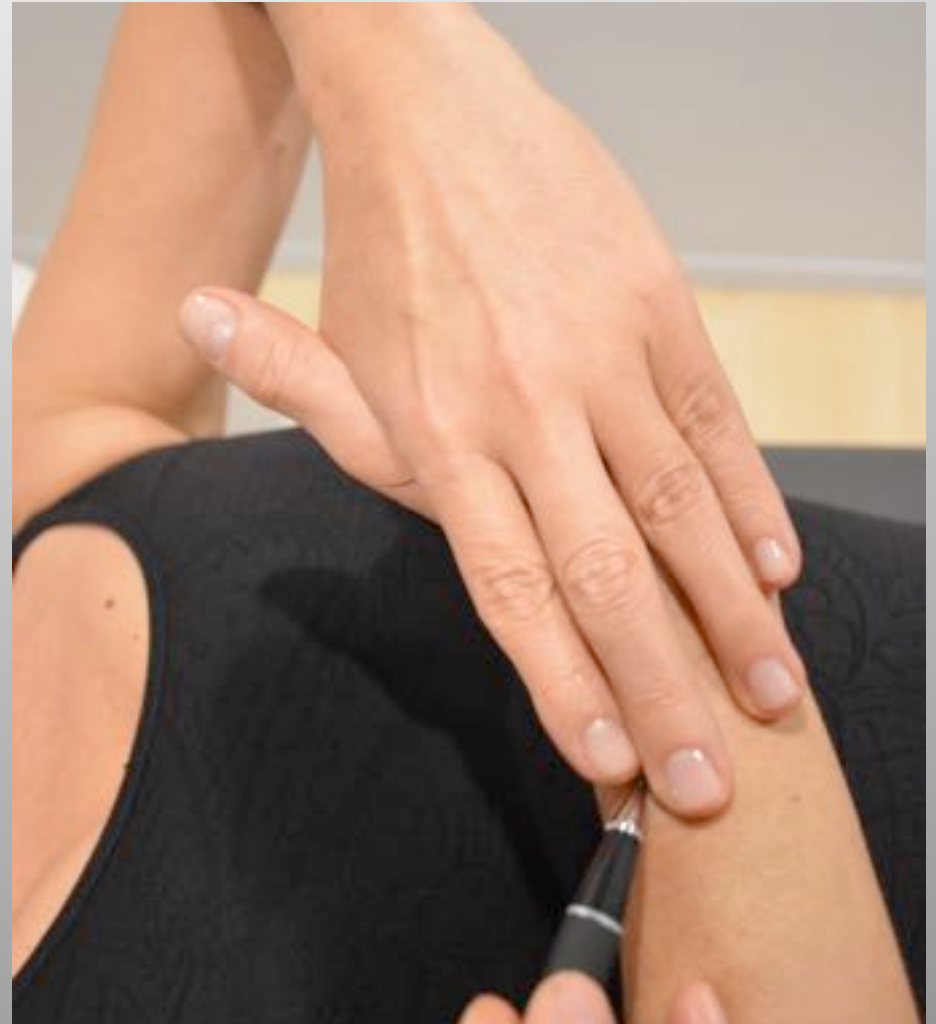


Japanese Large Intestine 6

Hand Yang Ming

Japanese LI 6

Master Hukaya states this point is best located when the patient places the second and third finger of one hand over the thumb of the patient hand, found on LI line between two fingers.



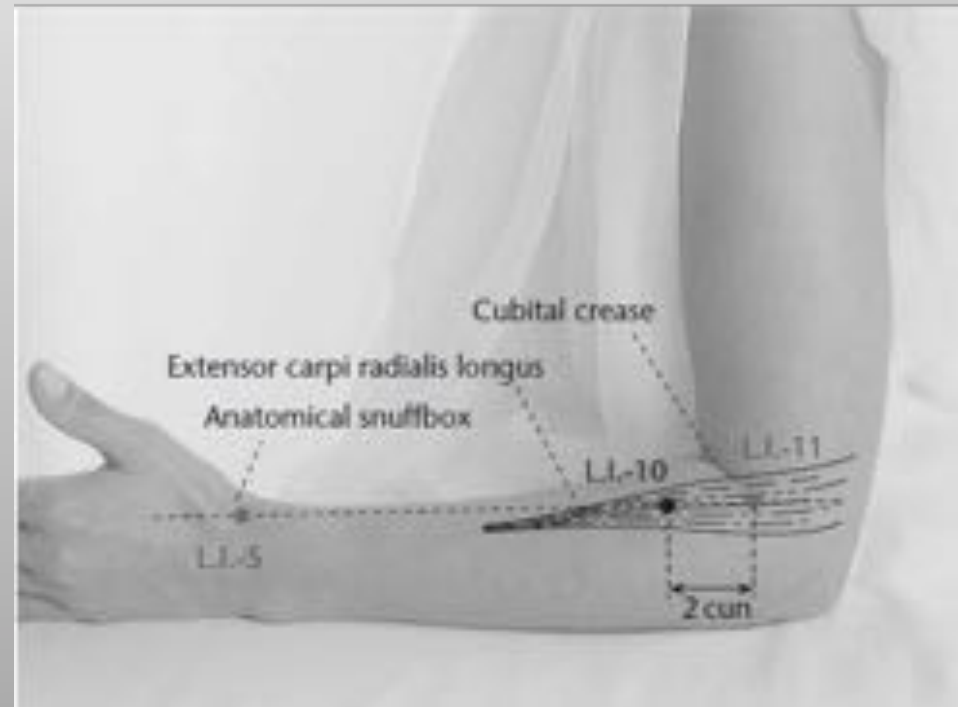
Large Intestine 10 Hand Yang Ming

LI 10 –(*Shousanli* –Arm Three Miles)

Located on the radial side of
the forearm, 2 cun distal to LI
11 on line connecting LI 11
with LI 5

LI 11 –(*Quchi* - Pool at the Crook)

Located at the elbow halfway
between TCM LU 5 and the
lateral epicondyle, at end of
transverse cubital crease

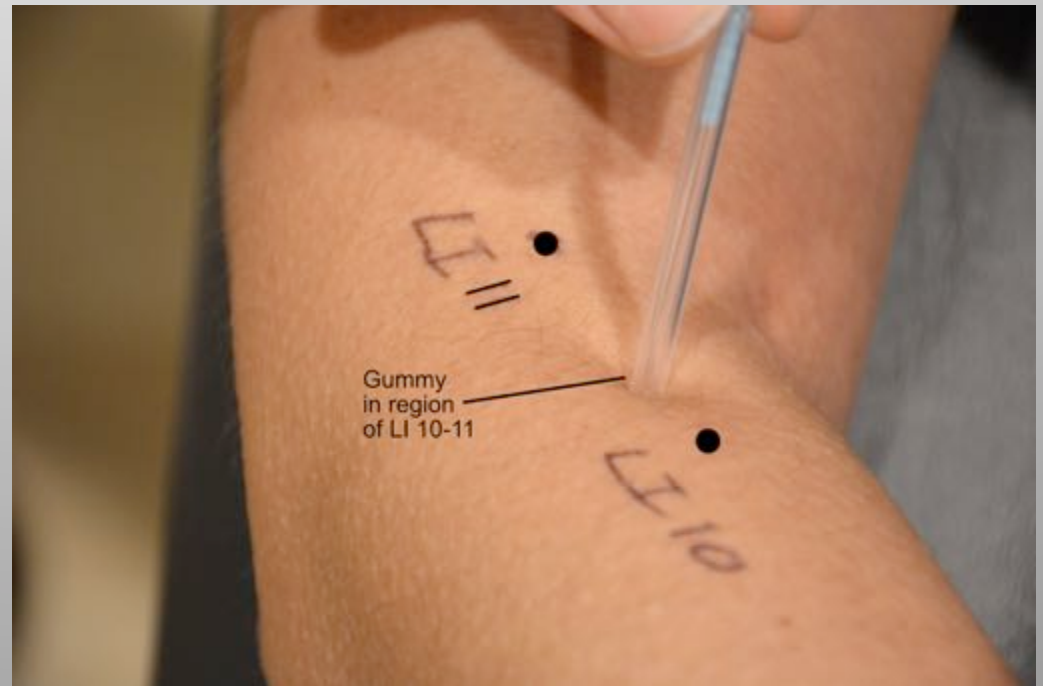


Japanese Large Intestine 10 - 11

Hand Yang Ming

Japanese LI 10 - 11

In region of LI 10 to 11 on extensor carpi radialis longus muscle belly looking for mylogeloses or “gummies”

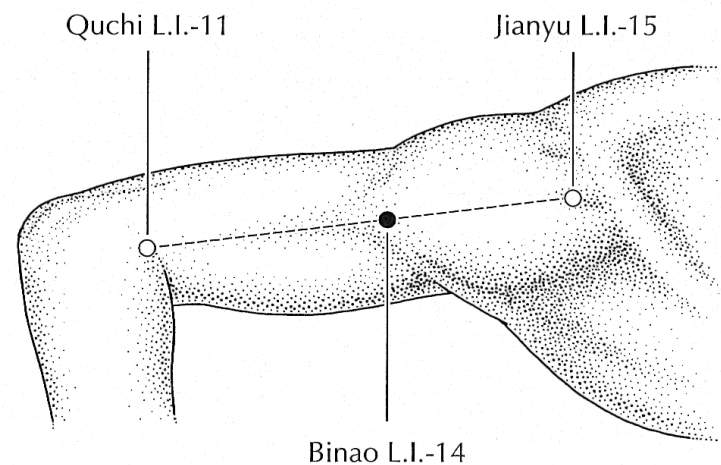
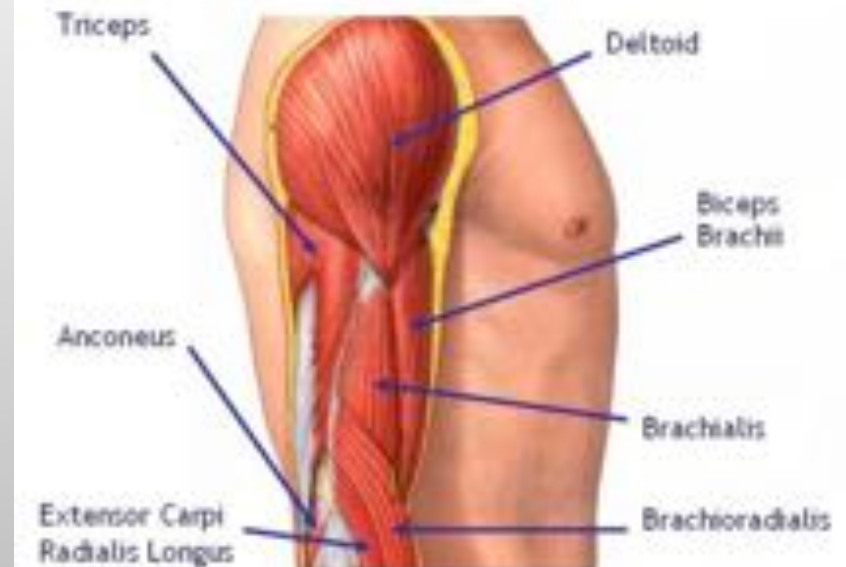

Large Intestine 14

Hand Yang Ming

LI 14 –(Binao –Upper Arm)

On the lateral side of upper arm, in the visible and tender depression between insertion of deltoid and brachialis muscles.



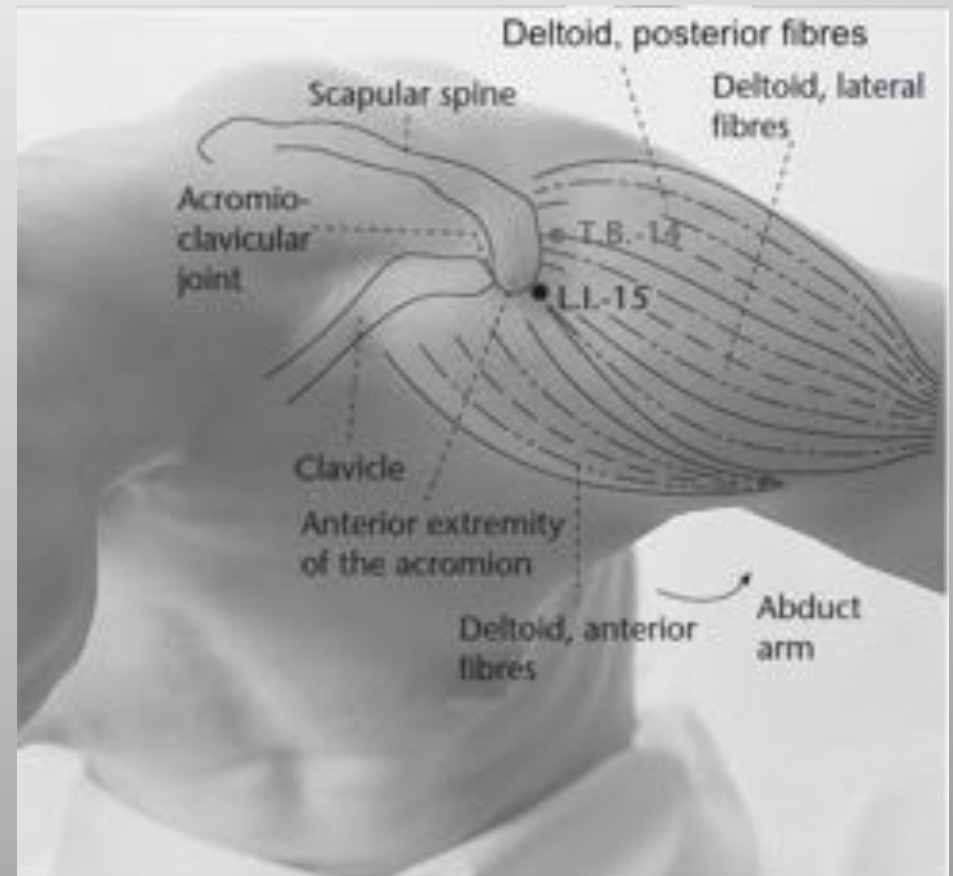
Large Intestine 15

Hand Yang Ming

LI 15 –(*Jianyu*-Shoulder Bone)

This point is best located and treated when the patient abducts their upper arm to the side along the shoulder line.

Then find the anterior depression just inferior to the acromion between the middle and anterior deltoid origins

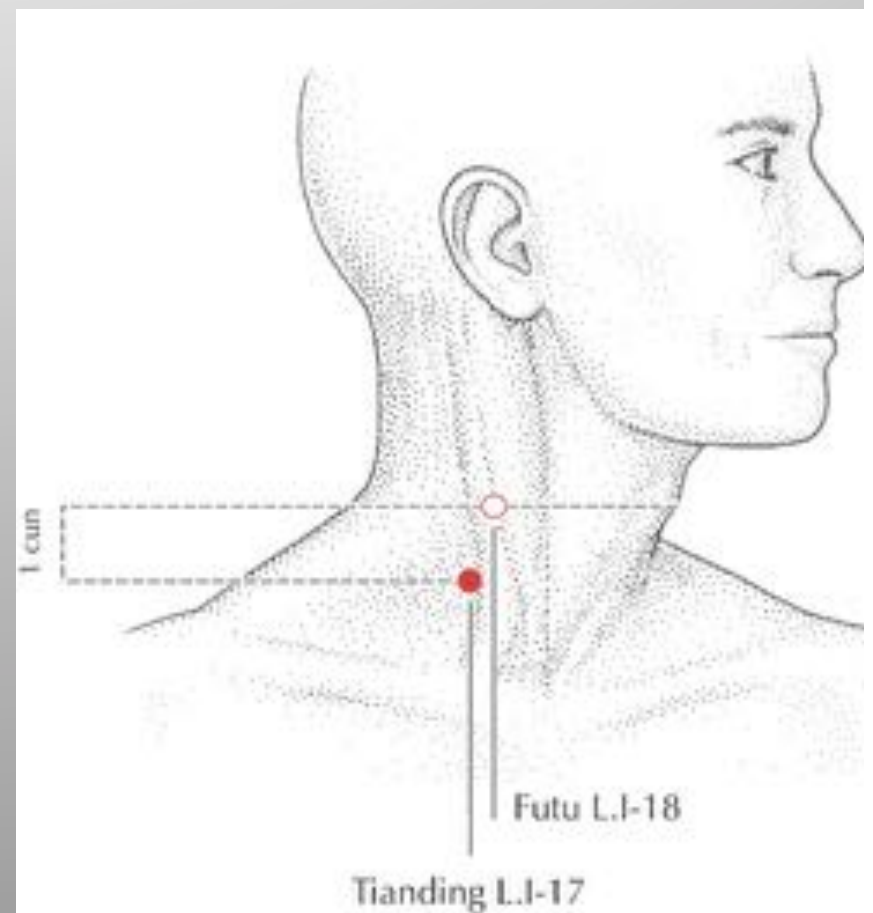


Large Intestine 17

Hand Yang Ming

LI 17 –(Tianding – Heavens Tripod)

Located on the lateral side of neck, 1 cun inferior to LI 18, which is at the level of the laryngeal prominence, on the posterior border of the Sternocleidomastoid muscle

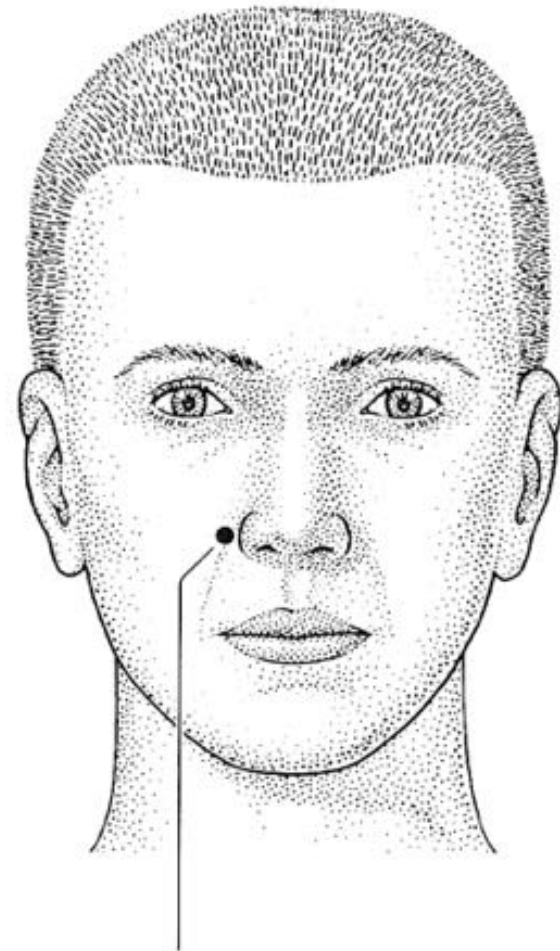

Large Intestine 20

Hand Yang Ming

LI 20 –(*Yingxiang* –
Welcome Fragrance)

Located in the crease
formed lateral to the
nose at the level of the
midpoint of the lateral
border of the ala nasi.



Yingxiang L.I.-20